

## A Preliminary Report on the Effect of Measured Strength Training in Adolescent Idiopathic Scoliosis

Vert Mooney, \*Jennifer Gulick, and †Robert Pozos

*U.S. Spine and Sport Center, \*World Wide Clinical Trials, and †San Diego State University, San Diego, California, U.S.A.*

---

**Summary:** The authors studied 12 adolescent patients with scoliosis (10 girls and 2 boys) who were 11 to 16 years old and had curvatures ranging from 20° to 60°. Seven were right thoracic curves and five were thoracolumbar with double curves. When tested on the MedX Torso Rotation Machine, both sides were unequal in their torso rotation strength all patients. Myoelectric activity was asymmetric in both sides and in abdominal and paraspinal muscles of all patients. These asymmetries were corrected completely with torso rotation, which was associated with significant strength gains. Strength gains ranged from 12% to 40%. A 16-year-old girl with a 60° lumbar curve progressed and had surgery. None of the remaining patients progressed, and 4 of the 12 had decreases in their curvatures from 20° to 28°. None of the patients used braces during this study. **Key Words:** Idiopathic scoliosis—Strength training—Scoliosis progression.

---

The cause of adolescent idiopathic scoliosis remains unclear. Many interrelated factors have been identified, but none clearly seems primary. One specific factor that may be relevant for treatment is the evidence of muscle asymmetry associated with curvature. The asymmetry has been noted in histologic and histochemical studies (7,9, 11,19,22). All studies seem to support a predominance of type 1 fibers on the convex side. Asymmetric myoelectric activity in the convex and concave sides also has been noted (8,16,17,24,25). There seems to be hyperactivity in the convex side. Even muscle mass as identified with real-time ultrasound has shown asymmetry (10). The lumbar multifidus area was found to be larger on the opposite side of the thoracic curve convexity and on the concave side of lumbar and thoracolumbar curves.

Surprisingly, with all this information on the asymmetry of muscle function in scoliosis, no data exist about the strength differentials between sides for adolescents with scoliosis. The effectiveness of exercise has not been shown. One preliminary study investigating the effects of

an exercise program in adolescents with minimal idiopathic scoliosis has been reported (20). This exercise program included the combination of sit-ups, leg lifts, pelvic tilts, and so forth. But there was no particular rationale. Each exercise was to be performed 10 times once a day. No significant difference in curvature was found between the exercise group and the control group. The exercise group was told to do each of the exercises 10 repetitions once a day, but the authors noted that most patients did not exercise according to their instructions. Only 59% could remember the exercises taught to them. Strength measurements to document change or compliance were not made. No other measurement of compliance was presented.

Because morphologic differences between sides have been demonstrated, we wanted to determine if a relation exists between torso strength and scoliosis. There is some evidence that a significant asymmetric increase in strength can cause scoliosis. A Scandinavian study found that among elite athletics with asymmetric strength required in the trunk and shoulders, such as javelin throwers and tennis players, a small thoracic curvature of approximately 10° occurs in more than 80% of participants who develop their skills during adolescence (21).

Swimming has been considered a prophylactic exercise for persons with scoliosis. Becker (4) performed an extensive study in which 336 Junior Olympic swimmers

---

Received June 9, 1999; accepted September 27, 1999.  
Address correspondence and reprint requests to Dr. V. Mooney, U.S. Spine and Sport Center, 3444 Kearny Villa Rd. #205, San Diego, CA 92123, U.S.A. Jennifer Gulick is currently at UCSD Orthomed Center, San Diego, CA.

were evaluated for scoliosis. Sixteen percent had mild functional curves, all with the convex curvature on the hand-dominant side of the body. This suggests that muscle imbalance is a possible contributor to scoliosis.

However, exercise as a therapeutic regimen needs to be measured. In addition, if it is to be effective, compliance must be consistent and monitored, and progress should be evaluated. Objective information about the effect on muscle activity can be achieved only with standardized measurement tools.

With that in mind, we performed a small pilot study using specialized equipment to measure torso strength in adolescents participating in progressive strength training. In addition, to evaluate muscle activity, we used surface electrodes to evaluate comparative torso myoelectric activity.

## MATERIALS AND METHODS

We used the MedX Rotary Torso Machine (Ocala, FL, U.S.A.) for torso rotation strength training and measurement of relative torso rotation (Fig. 1). The pelvis is stabilized in a sitting position and the torso is free to move in as much as a 96° arc rotating to the left or right, or *visa versa*. For the purpose of this study, torso rotation was restricted to 36° in each direction. Thus, full torso rotation from one direction or the other is 72°. With this device, there is a stop at every 18°, at which isometric strength can be measured. Thus, for the full 72° arc rotating from 36° on the left to 36° on the right, for instance, there are five measurement positions for isometric strength. Rotation is resisted in the exercise mode by a weight stack, with resistance being translated to the rotary axis by a cam so that a constant resistance is present through the full arc. This is

typical of Nautilus-type devices. Thus, in this exercise mode, the amount of resistance is known and the number of repetitions before fatigue occurs is recorded. Typically, when 20 repetitions at one level of resistance can be accomplished, the resistance is increased by approximately 5% at the next exercise session. Initially, the participants exercised twice a week, but when near equal left and right strength was achieved, exercise sessions were reduced to once a week. The exercise regimen was performed for 4 months. The exercise was both in the eccentric and concentric mode, to the left and to the right.

Testing on the machine was done at monthly intervals. The isometric pattern, starting and end point, could be printed (Fig. 2). The mode of testing was in the direction of exercise (i.e., left to right or right to left). Because the muscles are at greatest strength at the starting point, full rotation to the right on the occasion of left rotation testing, the isometric strength was typically strongest in that position and decrease gradually to a considerably lesser amount at full left rotation (36°). In this way, differences in left and right rotation strength could be monitored, and change in strength at a monthly level could be defined in addition to monitoring the change in resistance on the occasion of the dynamic exercise.

Myoelectric activity was monitored (ME 3000 Mega Electronics, Kuopio, Finland) in the upper lumbar paraspinal muscles, apparently the multifidus. The electrodes were placed 2 inches from the midline on the left and right just below the lowest rib. Additional electrodes were placed on the upper abdomen overlying the oblique muscles, again 2 inches from the midline and 2 inches below the rib cage on the left and right. The same positioning was used in all participants.

Twelve adolescents were recruited for this study (Table




FIG. 1. The MedX Torso Rotation unit illustrates isolation of torso rotation capacity, the measurable resistance feasible with a weight stack, and computerized feedback, which can demonstrate performance.

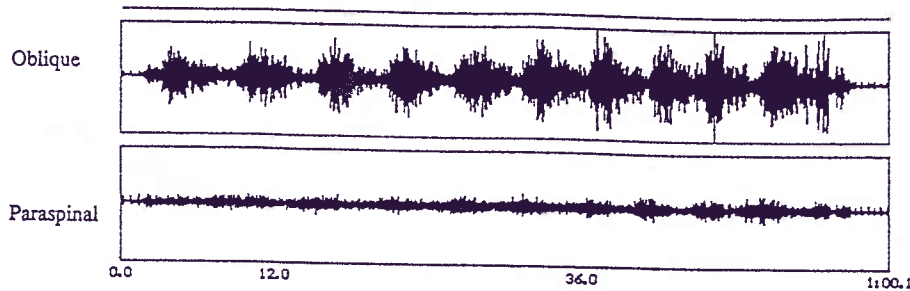


FIG. 3. A typical myoelectric pattern at the beginning of the study shows diminished paraspinal activity.

None of the remaining participants progressed, and curvature decrease from 20° to 28° in four of the girls. None of the patients wore braces during the time of this study.

### DISCUSSION

The purpose of this pilot study was not to find a cure for adolescent scoliosis. It does document, however, that there is a consistent asymmetry in torso rotation strength that can be shown with specific strength testing and with myoelectric activity. This is definitely abnormal.

In that an asymmetric rotation strength deficit is so consistently demonstrable, strength training would seem to be a rational therapeutic approach. The failure in the past of exercise training to show effective treatment for adolescent idiopathic scoliosis may be ascribed to many factors. Certainly without a specific piece of equipment, isolation of appropriate musculature is not possible. In addition, without specific equipment, strength change cannot be measured. Finally, as was shown by Stone et al. (20), compliance by otherwise healthy pain-free adolescents is a considerable problem. In our study, the minimal demand on time, along with the objective evidence of improvement in strength (positive biofeedback), were important inducements for continued compliance. None of the participants dropped out of the study. Sometimes social events and family vacations interfered with complete consistency, but the children always started back in their exercise program as soon they were available.

Electric muscle stimulation was once thought to be an advance in exercise treatment for scoliosis. Results of early clinical studies were encouraging (5,6). Axelgaard et al. (3) showed in animal studies and in clinical practice the

correction of spinal curvature. However, when applied to a broad group of adolescent patients with scoliosis, it was found to be ineffective (15). In this study of 25 patients with curvatures between 25° and 35°, one was improved and 10 became worse. It was thought to be ineffective and no better than natural history.

In all of the articles that discuss electric stimulation, there was no before and after strength testing, or comparative electromyographic studies. It must be recognized that surface electrode stimulation of peripheral muscles does not bring the central nervous system into facilitation of muscle activity. Electric stimulation alone has never been shown to change electromyographic patterns.

Of course, specific exercise training cannot be proposed to replace standard nonoperative brace therapy. Brace therapy, however, as with unmeasured exercise, is certainly complicated by patient noncompliance. This may be a factor in its efficacy. Clinicians are aware that efficacy is not universal. In a series of 1,020 patients who wore braces for significant scoliosis, Lonstein and Winter (12) found a lack of significant progression in 78%, but they recommended longer bracing beginning with a curve at 25° to gain that level of success. There still remains some question about the utility of bracing. Noonan et al. (14) believe that bracing did not significantly change the natural history in their series of 111 patients.

In an attempt to summarize current status, a meta-analysis of the efficacy of nonoperative treatments for idiopathic scoliosis supported bracing if it was used 23 hours per day and showed it to be less effective if worn for less time (23). Conversely, in a recent survey of the literature, exercise was not mentioned (18).

There is also some question as to what happens to

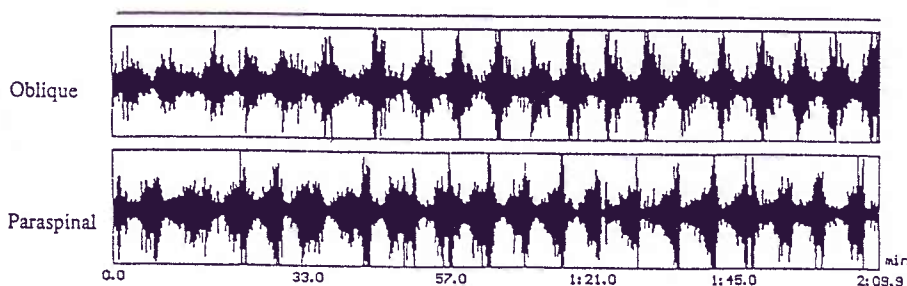


FIG. 4. A myoelectric pattern at the conclusion of the study shows a response to training with a substantial increase in activity.

